

A masquerading mass: an unusual presentation of IgG4-related systemic disease with tubulointerstitial nephritis

¹B Quinn, ²J Harty, ³W Habeichi

¹Foundation Year 2 doctor; ²Consultant Nephrologist; ³Specialist registrar, Daisy Hill Hospital, Newry, Northern Ireland, UK

ABSTRACT IgG4 tubulointerstitial nephritis (IgG4-TIN) is the most common form of IgG4 renal disease. When IgG4-TIN is accompanied by other systemic manifestations the disease is known as IgG4-related systemic disease (IgG4-RSD). IgG4-RSD is well recognised in the form of tubulointerstitial nephritis (IgG4-related TIN) and may present with renal failure by mimicking neoplasms (tumefactive lesions) or with both features. We describe a case of IgG4-RSD initially presenting as a submandibular mass and subsequently presenting two years later with secondary infiltration of the kidney causing tubulointerstitial nephritis. This case highlights the importance of recognising IgG4-RSD as a non-malignant disease with presentations having commonly shared features including tumour-like swelling of involved organs and its ability to mimic many systemic diseases. In the majority of patients it can be treated successfully with corticosteroids.

KEYWORDS chronic sclerosing sialadenitis, IgG4-related systemic disease (IgG4-RSD), Küttner's tumour, tubulointerstitial nephritis

DECLARATION OF INTERESTS No conflict of interest declared.

Correspondence to J Harty
Daisy Hill Hospital Renal Unit
5 Hospital Road
Newry BT35 8DR
Co. Down, Northern Ireland, UK

tel. +44 (0)2830 835035
e-mail john.harty@southerntrust.hscni.net

IgG4-related systemic disease (IgG4-RSD) is a relatively new clinical disease; it was first proposed in 2001 by Hamano et al. who reported it as a case of autoimmune pancreatitis with high tissue infiltration levels of IgG4.¹ Many organs and tissues demonstrate tissue infiltration with a predominance of IgG4-positive plasma cells and T lymphocytes. IgG4-RSD causes fibrosis and a deposit of connective tissue within the affected organ, for example the submandibular gland (chronic sclerosing sialadenitis – Küttner's tumour), the kidneys (tubulointerstitial nephritis) and membranous glomerulonephritis (MGN).²

Many patients may have unidentified disease dormant within a particular organ for many years, while others may present sub-acutely with major organ damage. Multi-organ disease can therefore present fortuitously or manifest over months to years. Elevated serum and tissue levels of IgG4 are useful markers in helping to diagnose IgG4 disease. However, histopathological features are required to confirm a diagnosis of IgG4-RSD.³

CASE REPORT

Three months after a simple tooth extraction, a 54-year-old male presented to his general practitioner with a painless mass in the right anterior triangle of his neck, with a second mass developing within several days. Both masses were firm, painless and approximately equal in size. The patient was asymptomatic and had no difficulty eating or swallowing during his assessment. He was otherwise healthy, had a normal body mass index and

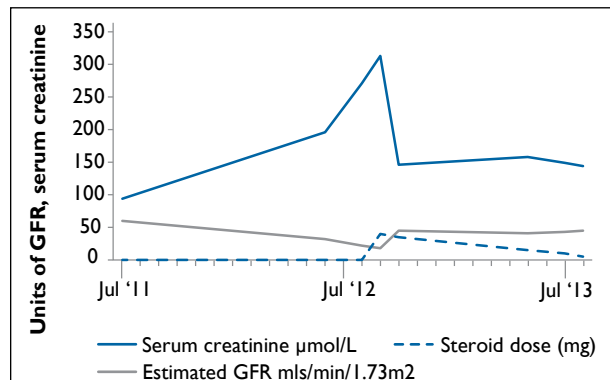


FIGURE 1 Serial serum creatinine ($\mu\text{mol/L}$) and estimated GFR (ml/min/1.73 m^2). Corticosteroid therapy was commenced two years after the patient's initial presentation.

was a non-smoker who did not consume alcohol.

Assessment by the oral maxillo-facial surgical department found symmetrically enlarged, well-defined, firm non-tender, non-fluctuant lesions in the submandibular triangles (5 cm right and 3 cm left). On manipulation, clear saliva was expressed from both parotid and submandibular gland ducts. The expression of saliva from the right submandibular gland was more indolent than on the contralateral side.

An ultrasound of the right submandibular salivary gland found no obvious duct dilatation. An ultrasound-guided fine needle aspiration was performed of the right submandibular gland only as it was felt that both glands

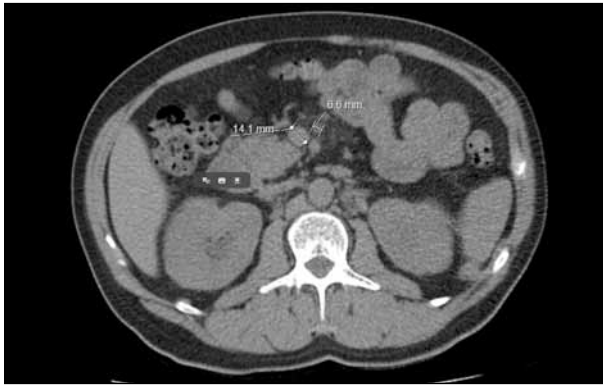

FIGURE 2 Mesenteric lymphadenopathy (arrow) can be seen in the upper abdomen with nodes measuring up to 8 mm in short axis. No hydronephrosis was found and there were no renal, ureteric or bladder calculi.

would have the same pathology. Histological features were consistent with a diagnosis of chronic sclerosing sialadenitis (Küttner's tumour). Immunohistochemical staining was not performed on the salivary biopsy. The patient was treated with conservative management and reviewed twice yearly by the maxillo-facial team.

Two years after the initial presentation, a routine biochemical screen noted that the patient's creatinine level of 94 $\mu\text{mol/L}$ had increased to 312 $\mu\text{mol/L}$ in 14 months, with a corresponding decrease in estimated glomerular filtration rate (eGFR) from normal (>60 ml/min/1.73 m^2) to 18 ml/min/1.73 m^2 (Figure 1). The total protein/creatinine ratio two years after the initial presentation was 125.6 mg/mmol (normal range 0–0.14), with an estimated 24-hour leakage equivalent of 1.105 g (normal range 0–0.14).

The patient was subsequently referred for an urgent nephrology assessment. On clinical examination, both submandibular salivary glands were found to be enlarged and non-tender. There was no abdominal or flank tenderness nor any palpable masses. An ultrasound of the renal tract was normal. An unenhanced volume computed tomography scan of the renal tract found no evidence of renal obstruction. However, mesenteric lymphadenopathy was present in the upper abdomen, with nodes measuring up to 8 mm (Figure 2). Liver function test and serum calcium were normal. Urinary Bence Jones protein, plasma electrophoresis, including a comprehensive renal vasculitic and antibody screen, identified high IgG levels at 43.70 g/L (normal range 6–16) (Table 1).

A ultrasound-guided biopsy of the left kidney showed tubulo-interstitial inflammation. Plasma cells were prominent within this infiltrate and there was evidence of tubulitis. The inflammation was associated with an exuberant fibrosing reaction within the interstitium which spilled out into the overlying capsule. Light microscopy identified changes consistent with sclerosing tubulo-

TABLE 1 A comprehensive renal vasculitic and antibody screen found high IgG and IgG4 levels at 43.70 g/L

Marker	Result	Reference
Complement C3	0.5 g/L	(0.75–1.65)
Complement C4	0.04 g/L	(0.14–0.54)
C-ANCA	negative	
P-ANCA	negative	
ANCA (atypical)	negative	
Rheumatoid factor	<10 IU/ml	(0–0.14)
Anti ds DNA antibody	<1 IU/ml	(0–4) negative
Anti chromatin antibody	<0.2 AI	(0–0.9)
Anti ribosomal P antibody	<0.2 AI	(0–0.9)
Anti RO 52 antibody	<0.2 AI	(0–0.9)
Anti 60 antibody	<0.2 AI	(0–0.9)
Anti LA antibody	<0.2 AI	(0–0.9)
Anti Sm antibody	<0.2 AI	(0–0.9)
Anti Sm/RNP antibody	<0.2 AI	(0–0.9)
Anti RNP A antibody	<0.2 AI	(0–0.9)
Anti RNP 68 antibody	<0.2 AI	(0–0.9)
Anti SCL 70 antibody	<0.2 AI	(0–0.9)
Anti Jo-1 antibody	<0.2 AI	(0–0.9)
Anti centromere B antibody	<0.2 AI	(0–0.9)
PR3 – ANCA	<0.2 AI	(0–0.9)
MPO ANCA		
Anti GMB antibody		
Total protein	91 g/L	(60–80)
IgG	43.70 g/L	(6.0–16)
IgA	1.34 g/L	(0.8–4)
IgM	0.69 g/L	(0.5–2)
Serum protein electrophoresis	none detected	

Abbreviations: ANCA: anti-neutrophil cytoplasmic antibody; Ig: immunoglobulin; GMB: glomerular basement membrane.

interstitial nephritis, with staining for kappa and lambda light chains showing a polyclonal plasma cell population with no evidence of light chain restriction. Considerable numbers of the plasma cells were positive for IgG4.

The patient was commenced on prednisolone 40 mg per day (Figure 1). Following regular clinical reviews, he reported an improvement in general well-being and, in particular, noted a significant reduction in the size of his salivary glands. Steroids were reduced in 5mg weekly decrements down to a dose of 20 mg/day. Steroids were then reduced by 5 mg every 2 weeks down to 10 mg/day. Subsequent reduction was by 2.5 mg/month down to a maintenance dose of 5 mg/day. After six months and on a dose of 5mg bloods, he had a normal serum IgG level of 14.67 g/L, with an IgG4 level of 0.32 g/L, creatinine of 132 $\mu\text{mol/L}$ and eGFR of 50 ml/min/1.73 m^2 . The protein/creatinine ratio was 8.6 mg/mmol with an estimated 24-hour equivalent protein leakage of 0.076g.

DISCUSSION

IgG4-RSD is a multi-system condition that can infiltrate and alter the normal functioning of several organs, a feature common with other disease processes such as lymphomas and sarcoidosis. While IgG4-RSD and other similar conditions manifest with strikingly similar symptoms and dysfunction in many organs, it is accepted that there are histopathological features unique to IgG4-RSD allowing for its differentiation and diagnosis.

To date no definitively agreed international guidelines exist for the diagnosis of IgG4-RSD. However, hallmark findings for a diagnosis of IgG4-RSD include lymphoplasmacytic infiltration with storiform fibrosis (Figure 3a), obliterative phlebitis or arteritis and IgG4 immunohistochemical staining demonstrating high ratio of IgG4-positive plasma cells to the overall number of plasma cells in tissue (Figure 3b). A diffuse plasma-rich infiltrate with a ratio of IgG4 to IgG greater than 50% and more than 30 IgG4-positive cells per high-power field proves compelling when present with characteristic histopathological appearance.³ These histological and immunophenotypic features on a pathologic specimen when present are considered the 'gold standard' for diagnosis.^{3,4} Histopathological features present with sarcoidosis include non-caseating granulomas irrespective of tissue type and therefore allow for a distinctive differentiation via biopsy.

Chronic sclerosing sialadenitis (Küttner's tumour) is a fibroinflammatory disease of the salivary gland with distinctive morphological appearance. However, when such inflammation is present with elevated tissue IgG4 infiltration, it is distinguished from other inflammatory diseases of the salivary glands and as such belongs to the spectrum of IgG4-related diseases (IgG4-RSD), thus complying with accepted guidelines as reported by many authors.^{1,5} Management of Küttner's tumours can be conservative, depending on the patient's symptoms. A 'watch and wait' approach is accepted where the patient is asymptomatic, comfortable and the lesion(s) are confirmed as being benign.⁶

IgG4 immunoglobulin is the rarest subtype of the IgG class, accounting for less than 6% of total IgG protein. When abnormal levels of IgG4 are found, they typically occur more frequently in middle-aged and older men, with a male to female ratio between 2:1 and 4:1.⁷⁻⁹ While serum levels can suggest the possible presence of IgG4, disease they are not diagnostic without histopathological and immunohistochemical staining for IgG4.

The clinical significance of isolated elevations of serum IgG4 concentrations remains uncertain,³ with serum IgG4 concentrations normal in 30% of patients despite histopathological and immunohistochemical findings on biopsy.¹⁰ One source reports that IgG4 levels are elevated in 5% of the normal population.⁵ The most

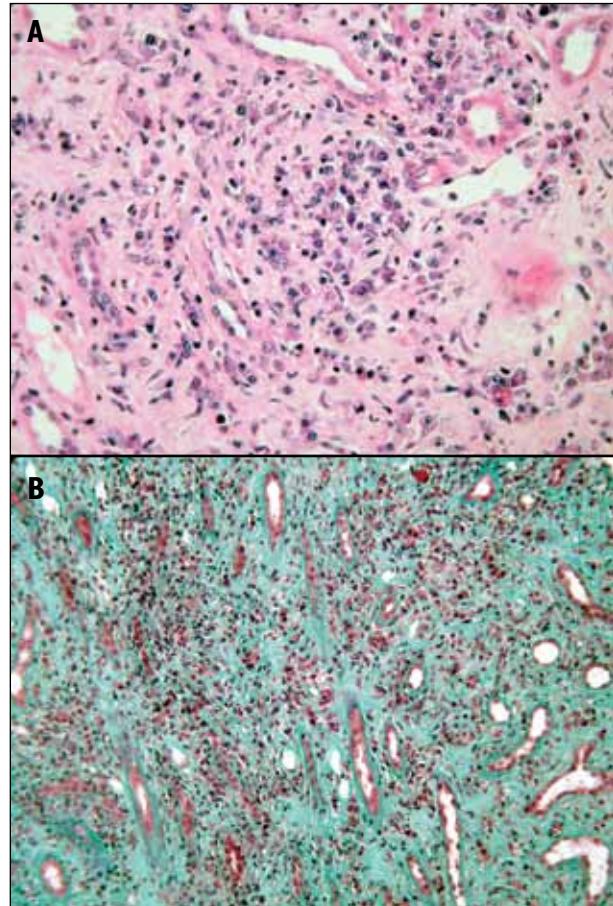


FIGURE 3 A: Hematoxylin and eosin stain: the IgG4 lymphoplasmacytic infiltrate has storiform fibrosis (circular pattern). B: Tubulointerstitial nephritis with sclerosis and plasma cell-rich infiltrate. Masson trichrome to show sclerosis and immunohistochemical stain for IgG4 to show IgG4 plasma cells.

common sites for IgG4 accumulation are the pancreas and lung. However, it may occur in other tissues, including the salivary glands, kidneys, hepatic portal tract, prostate and retroperitoneal tissue.

Given the insidious presentation of IgG4 and the difficulty in correlating clinical findings, a diagnosis may only be reached with tissue sampling. Identifying sub-clinical disease in secondary organs can be challenging; cross-sectional imaging is effective in detecting any sub-clinical disease. Drawing a distinction between IgG4 disease and neoplastic disease is important. IgG4 is not a malignant disease and as such does not require treatments reserved for malignant conditions. No randomised control treatment trials have been conducted for IgG4-RSD to date. Treatment will be influenced by a patient's symptoms and depend on whether serious organ dysfunction is possible or imminent.

Reported cases of IgG4-RSD have adopted a 'watch and wait' approach for indolent and asymptomatic disease. However, IgG4 disease can lead to serious organ dysfunction; when required, an aggressive approach is recommended. Accepted first-line treatment is glucocorticoid, but no correlation has been found

between the extent of disease and the required steroid treatment.³ In patients with confirmed IgG4-RSD who have a poor response to steroids, non-glucocorticoid options have been proposed including azathioprine, rituximab and mycophenolate mofetil, but the effects of these glucocorticoid-sparing medications in IgG4-RSD have not been evaluated adequately to clearly define their role relative to other agents.

Steroids (prednisolone) can be initiated at 0.6 mg/kg per day on a reducing dose subject to improvements evident through blood markers, symptomatic response or via cross-sectional imaging. Most patients respond favourably to steroid treatment within weeks, with reductions in the size of masses or organ enlargement and improvements in organ function with resolving symptoms. When starting treatment with steroids, clinical and hematological improvements can be rapid, as was observed with our patient following regular clinical appointments – a finding that is consistent with treatment of other reported IgG4 cases.^{1,6,9,11} To date, our patient remains symptom-free with almost normal renal function.

The natural history of IgG4-RSD has not been well-defined or understood, with clinical cases reporting some patients improving spontaneously without treatment.^{1,3,5} However, many patients have relapses. Infiltration of IgG4 immunoglobulins within an organ in addition to infiltration of other organs can lead to significant morbidity and mortality depending on the organs affected. This sometimes happens despite apparently effective treatment; therefore aggressive and persistent treatment may be needed.

No agreed criteria exist regarding the long-term treatment of this condition. As such, treatment requires adjustment,

with tapering of steroids after three to six months and a low dose maintained over periods up to three years.³ While IgG4 is a non-malignant condition, several types of lymphoma have been reported to date in patients with IgG4-RD in both Japan and North America.^{12–14} Despite these publications, there is to date no confirmed risk attributed to developing cancer with IgG4-RSD and the risk of malignancy in patients with IgG4-RSD requires further study.

CONCLUSION

An unusual case of IgG4-related systemic disease has been described following its initial presentation as a submandibular neck mass with local lymphadenopathy. With no immunohistochemical staining on the initial salivary biopsy, a cause was not established for the salivary gland enlargement, but conservative treatment was taken following a benign biopsy. Secondary infiltration to renal tissue resulted in tubulointerstitial nephritis. This condition responded well to treatment with steroids.

Following a diagnosis of IgG4-RSD clinicians should carefully consider clinical history and physical examination, paying particular attention to salivary glands (submandibular or parotid enlargement), biliary tree, pancreas and eyes (lacrimal gland enlargement, orbital pseudotumour). IgG4-RSD is a condition that most often occurs in middle-aged and older men. It can be a collection of disorders that share specific pathological, serological and clinical features. While this case highlights an example of an uncommon disease, it encourages medical practitioners to be mindful of the variety of delayed clinical presentations exhibited in IgG4 disease, its potential to mimic several conditions and the good clinical response that typically results in steroid treatment.

REFERENCES

- Hamano H, Kawa S, Horiuchi A et al. High serum IgG4 concentrations in patient with sclerosing pancreatitis. *N Engl J Med* 2001; 344:732–38.
- Cheuk W, Chan JK. IgG4-related sclerosing disease: a critical appraisal of an evolving clinicopathologic entity. *Adv Anat Pathol* 2010; 17:303–32. <http://dx.doi.org/10.1097/PAP.0b013e3181ee63ce>
- Stone JH, Zen Y, Deshpande V. IgG4-related disease. *N Engl J Med* 2012; 366:539–51. <http://dx.doi.org/10.1056/NEJMra1104650>
- Geyer JT, Ferry JA, Harris NL et al. Chronic sclerosing sialadenitis (Küttner tumor) is an IgG4-associated disease. *Am J Surg Pathol* 2010; 34:202–10. <http://dx.doi.org/10.1097/PAS.0b013e3181c811ad>
- Ryu JH, Horie R, Sekiguchi H et al. Spectrum of disorders associated with elevated serum IgG4 levels encountered in clinical practice. *Int J Rheumatol* 2012; 2012:232960. <http://dx.doi.org/10.1155/2012/232960>
- Kivernti E, Singh A, Clarke P. Küttner's tumour: an unusual cause of salivary gland enlargement. *Hippokratia* 2008; 12:56–8.
- Raission Y, Nasr SH, Larsen CP et al. Diagnosis of IgG4-related tubulointerstitial nephritis. *J Am Soc Nephrol* 2011; 22:1343–52. <http://dx.doi.org/10.1681/ASN.2011010062>
- Nishikawa G, Nakamura K, Yamada Y et al. Inflammatory pseudotumors of the kidney and the lung presenting as immunoglobulin G4-related disease: a case report. *J Med Case Rep* 2011; 5:480. <http://dx.doi.org/10.1186/1752-1947-5-480>
- Shoji S, Nakano M, Usui Y. IgG4-related inflammatory pseudotumor of the kidney. *Intern J Urol* 2010; 17:387–8.
- Sah RP, Chari ST. Serologic issues in IgG4-related systemic disease and autoimmune pancreatitis. *Curr Opin Rheumatol* 2011; 23:108–13. <http://dx.doi.org/10.1097/BOR.0b013e31813469>
- Cornell LD, Chicano SL, Deshpande V et al. Pseudotumors due to IgG4 immune-complex tubulointerstitial nephritis associated with autoimmune pancreatocentric disease. *Am J Surg Pathol* 2007; 31:1586–97.
- Sato Y, Ohshima K, Ichimura K et al. Ocular adnexal IgG4-related disease has uniform clinicopathology. *Pathol Int* 2008; 58:465. <http://dx.doi.org/10.1111/j.1440-1827.2008.02257.x>
- Takahashi N, Ghazale AH, Smyrk TC et al. Possible association between IgG4-associated systemic disease with or without autoimmune pancreatitis and non-Hodgkin lymphoma. *Pancreas* 2009; 38:523. <http://dx.doi.org/10.1097/MPA.0b013e31819d73ca>
- Cheuk W, Yuen HK, Chan AC et al. Ocular adnexal lymphoma associated with IgG4+ chronic sclerosing dacryoadenitis: a previously undescribed complication of IgG4-related sclerosing disease. *Am J Surg Pathol* 2008; 32:1159–67. <http://dx.doi.org/10.1097/PAS.0b013e31816148ad>