

# Disseminated bacillus Calmette-Guérin (BCG): a cause of delirium in an older adult

John Headlam<sup>1</sup>, Alice Wheeler<sup>2</sup>, Keith Yuen<sup>3</sup>, Elizabeth Brierley<sup>4</sup>, Oliver Todd<sup>5</sup>

## Abstract

Intra-vesical Bacillus Calmette-Guérin (BCG) immunotherapy is an effective treatment for high-risk bladder cancer. Less well known is that fewer than 1% of patients receiving BCG treatment can develop disseminated BCG. The reaction can range from a mild flu-like illness to a systemic disorder with a fulminant course which in the most severe cases can lead to death. The diagnostic yield is low and diagnosis is often made after a comprehensive

exclusion of more common causes of pyrexia of unknown origin. A high level of suspicion is therefore required in those who may be at risk. We report a case of disseminated BCG in an older patient for whom early involvement of his family was pertinent to determining the precipitant for delirium.

**Keywords:** disseminated, granulomatous, collateral, pyrexia of unknown origin, BCGosis

**Financial and Competing Interests:** This work was supported by Dunhill Medical Trust, UK [RTF107/0117 to OMT]

**Informed consent:** Written informed consent for the paper to be published (including images, case history and data) was obtained from the patient for publication of this paper, including accompanying images.

## Correspondence to:

Oliver M Todd  
Academic Unit for Ageing  
and Stroke Research  
University of Leeds  
Bradford Teaching Hospitals  
NHS Foundation Trust  
Bradford BD9 6RJ  
UK

## Email:

[o.todd@leeds.ac.uk](mailto:o.todd@leeds.ac.uk)

## Case presentation

A 79-year-old man was referred with a month's history of being generally unwell with fever, rigors, new confusion and weight loss. The patient was a retired economics lecturer, lived with his wife and pet dog, maintained independence in all activities of daily living and continued to drive. There was no history of recent travel.

He had a significant past medical history including: four malignancies diagnosed in the last five years. He had had a basal cell carcinoma in the context of recurrent scalp actinic keratosis, which was removed in March 2018. Adenocarcinoma of the lung (T1b N0 M0) and prostate (Gleason 4+5, T3a N1 M0) had been treated respectively with radical radiotherapy to the lung in May 2015 and radiotherapy to the whole pelvis and prostate in September 2016. For the latter he also received 18 months of androgen deprivation therapy but he did not complete the full course because of side effects. There was no evidence of recurrence of cancer at either of these two sites since. He had also suffered a transient ischaemic attack (TIA) in 2016 and had an established history of chronic obstructive pulmonary disease, benign retrosternal goitre, recurrent episodes of anxiety and depression, glaucoma, recurrent uveitis and deafness.

Following investigation for visible haematuria, he was diagnosed with bladder cancer and in October 2017 underwent trans-urethral resection of bladder tumour (TURBT) followed by single instillation of mitomycin. Histology revealed high-grade non-muscle invasive urogenital carcinoma (Grade 3, pT1) and he was offered a standard regimen of 15 Bacillus Calmette-Guérin (BCG) instillations starting in January 2018, which comprised an induction course of six instillations followed by three maintenance courses of three instillations with cystoscopic surveillance in between. Cystoscopic surveillance revealed no disease recurrence.

After the tenth BCG instillation in September 2018, he developed shivers which resolved within four days. Following the 11th BCG instillation, one week later, BCG therapy was interrupted because the patient developed sustained fever and new urinary retention. He was admitted to hospital and treated empirically for a urinary tract infection with intravenous co-amoxiclav followed by a week's course of oral ciprofloxacin. Before discharge home he was also trained to intermittently self-catheterise to relieve retention in the future. Microscopy and culture of urine, submitted after therapy had been started, showed no growth.

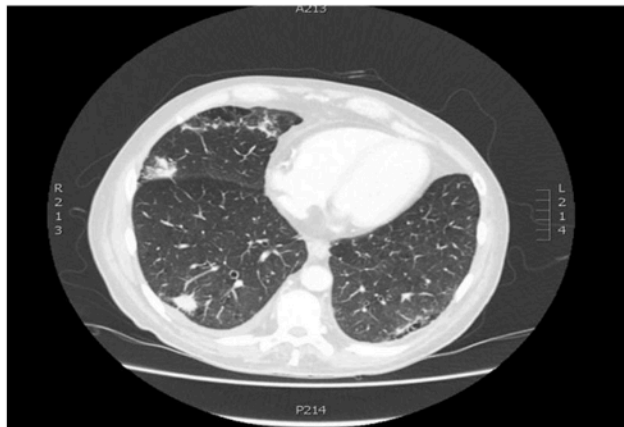A fortnight following discharge, in mid-October 2018, the patient continued to suffer fever. At this stage, he was

<sup>1,2</sup>Geriatric Registrars, Bradford Teaching Hospitals NHS Foundation Trust, Bradford, UK; <sup>3</sup>Urology Registrar, Bradford Teaching Hospitals NHS Foundation Trust, Bradford, UK; <sup>4</sup>Consultant Geriatrician, Bradford Teaching Hospitals NHS Foundation Trust, Bradford, UK; <sup>5</sup>Research Fellow, Academic Unit for Ageing and Stroke Research, University of Leeds, UK

**Table 1** Investigations undertaken

Investigation	Result (laboratory normal range) units
<b>Haematology and biochemistry (admission bloods)</b>	
Haemoglobin	98 (130 – 180) g/l
White blood cells	2.94 (4 – 11) x 10 <sup>9</sup> /l
Neutrophils	2.33 (1.8 – 7.5) x 10 <sup>9</sup> /l
Lymphocytes	0.53 (1.0 – 4.0) x 10 <sup>9</sup> /l
Platelets	99 (150 – 400) x10 <sup>9</sup> /l
C-reactive protein	90 (0 – 10) mg/l
Sodium	127 (133 – 146) mmol/l
Potassium	3.4 (3.5 – 5.3) mmol/l
Urea	7.4 (2.5 – 7.8) mmol/l
Creatinine	77 (64 – 104) umol/l
Electronic glomerular filtration rate (eGFR)	82 (90 – 500) ml/min/1.73m <sup>2</sup>
Bilirubin	25 (0 -21) umol/l
Alkaline phosphatase	657 (30 – 130) IU/l
Alanine aminotransferase	88 (5 – 45) IU/l
Albumin	15 (35 – 50) g/l
Prostate-specific antigen	0.05 (0 – 5) ng/ml
<b>Microbiology</b>	
Blood microscopy and bacterial culture	Negative
Urine microscopy and bacterial culture	
Throat swab Polymerase chain reaction (PCR)	
Atypical pneumonia screen for <i>Chlamydia</i> and <i>Legionella</i>	
QuantiFERON-TB (interferon-gamma release assay (IGRA))	
Alcohol and Acid Fast Bacilli (AAFB) microscopy and bacterial culture of urine	
Alcohol and Acid Fast Bacilli (AAFB) microscopy and bacterial culture of blood x 4	
<b>Microscopy</b>	
Cerebrospinal fluid	Clear, colourless, no organisms, lymphocytes <1 cm. Normal protein. Viral screen negative Cytology & AAFB negative
<b>Pathology</b>	
Bone marrow biopsy	Reactive cells, no evidence of haematological malignancy
<b>Virology</b>	
Human Immunodeficiency virus (HIV), Hepatitis B surface antigen (HBV sAg), Hepatitis C virus (HCV)	Negative
<b>Immunology</b>	
Anti-nuclear antibodies (ANA); anti-neutrophil cytoplasmic antibody (ANCA); Rheumatoid factor	ANA Negative; p-ANCA Positive; MPO/PR3 negative; Rheumatoid factor 68 (range 0 -20) IU/ml
<b>Radiology</b>	
Chest radiography	Post radiotherapy chronic scarring in the left mid zone. New bi-basal peri-bronchial patchy consolidation.
Ultrasound abdomen	No evidence of biliary obstruction or cholangitis. Incidental thick walled bladder.
Computed tomography (CT) of body	Multifocal areas of consolidation, a right pleural effusion, bi-basal patchy changes suggestive of possible infection/malignancy (Figure 1)
Magnetic resonance (MR) cholangiopancreatography	Normal appearance
MR imaging of head	No source of infection and no evidence of intracranial metastases
Echocardiogram	Intact anatomy and function, normal valve opening

**Figure 1** Computerised Tomography (CT) cross-sectional image of the bases of both lungs demonstrating multifocal consolidation



initially reluctant to attend hospital again so the hospital community team visited him at home and after two days he was persuaded to be re-admitted.

On admission his blood pressure was 135/90 mmHg, temperature 38.5°C, heart rate 79 beats per minute, and respiratory rate 20 breaths per minute, saturating 91% on air. Initial examination revealed him to be mildly inattentive, but orientated, with non-icteric sclerae and dry mucous membranes. There were no stigmata of endocarditis and no palpable lymph nodes. Auscultation revealed fine crepitations in the right lower zone, normal heart sounds and no signs of heart failure. His abdomen was soft and non-tender with no organomegaly. Bladder scan revealed a residual volume of 400ml. Peripheral and central neurology were normal and calves were soft and non-tender.

Blood tests revealed a pancytopenia with newly deranged liver biochemistry (Table 1). CT of the chest, abdomen and pelvis demonstrated dispersed multifocal areas of consolidation (Figure 1), and a right-sided pleural effusion too small to aspirate.

Fever persisted in spite of a 72-hour course of cefuroxime and metronidazole so that a comprehensive investigation for pyrexia of unknown origin was undertaken (Table 1). The patient had no history of tuberculosis (TB) otherwise. In the context of the investigations above and consultation with infectious disease specialists, empirical treatment for disseminated BCG was started on 26 October 2018.

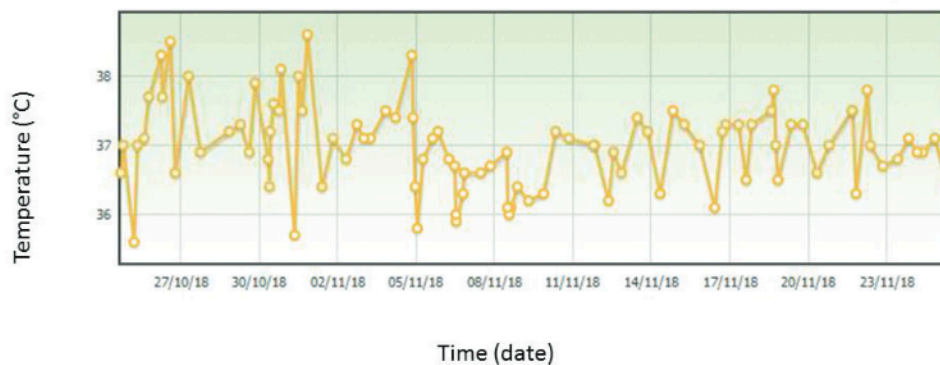
Nine days after commencing rifampicin, isoniazid and ethambutol, fever resolved (Figure 2) and clinical improvement was evident. Having been bedbound, he was able again to sit out of bed and there were signs he had become more attentive. However, liver biochemistry deteriorated on treatment reaching a peak alanine aminotransferase (ALT) of 241 and bilirubin of 102 on day 12 of antituberculous therapy. On day 13, treatment was changed to ethambutol 15mg/kg/day, levofloxacin 500mg once a day and amikacin 15mg/kg three times a week, whereupon liver biochemistry returned to normal so that the original choice of therapy could be re-instated.

Thereafter the patient made a gradual recovery. After four weeks he was mobilising around the ward and his delirium resolved so that he could be discharged for further physiotherapy and support at home. It was planned that he would complete a nine-month course of antituberculous treatment.

**Discussion**

BCG vaccine is a live-attenuated vaccine derived from *Mycobacterium bovis*. Intravesical use of BCG immunotherapy was first postulated in 1929 when it was noted that patients with TB demonstrated lower rates of cancer at autopsy.<sup>1</sup> Animal studies followed and in 1976 therapy was shown to be effective in nine individuals with recurrent superficial bladder cancer.<sup>2</sup> For transitional cell carcinoma, BCG remains a highly effective therapy and BCG is currently listed as a first-line treatment option for high-risk non-muscle-invasive bladder cancer in the United Kingdom.<sup>3</sup> The mechanism of action remains incompletely understood but it is likely that the host immune response stimulated by BCG is deleterious to the cancerous cells.<sup>4</sup> Anti-tumour effects appear greatest in patients who have a strong inflammatory reaction to treatment.<sup>5</sup>

Reactions to BCG treatment can be categorised as local or systemic. Locally, irritative symptoms may represent granulomatous inflammatory changes involving the structures of the genitourinary tract (e.g. cystitis, epididymitis or prostatitis). Systemic side effects range in severity from a fever and malaise, typically within the first 48 hours of intravesical therapy, to disseminated granulomatous disease or BCG infection, which may be more insidious in onset but life threatening.<sup>6</sup> Disseminated BCG affects less than



**Figure 2** Temperature chart for the duration of the admission



1% of those treated,<sup>7</sup> but its manifestations are protean, including single-organ inflammatory disease (e.g. hepatitis, pneumonitis), subacute infection (e.g. mycotic aneurysm, osteomyelitis) or sepsis. Distinguishing hypersensitivity reactions to BCG from ongoing active BCG infection is difficult, and reactions may represent a combination of the two,<sup>8</sup> there is evidence that both antimicrobial and corticosteroid therapy may be effective.


Immunocompromise and mucosal damage have been implicated as potential risk factors for disseminated BCG disease.<sup>9</sup> Our patient had a history of extensive pelvic radiation for the diagnosis of prostate cancer in 2016, recently started to self-catheterise, and was clinically suspected of having a urinary tract infection although the latter was never proven by microscopy or bacterial culture. Each of these three factors in our patient's history may have contributed to significant mucosal damage thereby providing a portal for BCG bacilli to enter the blood or lymphatic systems.

The diagnostic yield from blood cultures is reported to be as low as 30%.<sup>6</sup> Biopsies of non-caseating granuloma, where these are evident, can enable histological examination or culture with much higher diagnostic yields at 70%.<sup>6</sup> Disease foci more amenable to biopsy include presentations where the prostate or bone is involved. However, biopsy is not

helpful in cases presenting with widespread systemic disease as in our patient. In other reported cases, mycobacterial DNA has been successfully identified in the bone marrow using deoxyribonucleic acid (DNA) hybridisation techniques<sup>10</sup> and in urine and liver specimens using polymerase chain reaction (PCR).<sup>11</sup> In the majority of patients with disseminated BCG, the diagnosis relies chiefly upon the exclusion of all reasonable alternatives, or following a positive response to antituberculous treatment.<sup>8</sup>

## Conclusion

The case we present demonstrates that in patients presenting with pyrexia of unknown origin following BCG immunotherapy, particularly within the first 24 hours of BCG instillation, clinicians should consider the possibility of disseminated BCG. If disseminated BCG is suspected, then treatment should not be delayed awaiting definitive microbiology as the diagnostic yield is low and consequences of the infection can be severe.

Perhaps most saliently, this case reiterated the necessity, particularly in older people presenting with delirium, of a careful review of a patient's medical records as well as discussing the history and clinical presentation with the family. 

## References

- Pearl R. Cancer and tuberculosis. *Am J Hyg* 1929; 9: 97–159.
- Morales A, Eiding D, Bruce AW. Intracavitary Bacillus Calmette-Guérin in the treatment of superficial bladder tumors. *J Urol* 1976; 116: 180–3.
- NICE Guideline. *Bladder cancer: diagnosis and management*. London: National Institute for Health and Care Excellence; 2015.
- Fuge O, Vasdev N, Allchorne P et al. Immunotherapy for bladder cancer. *Res Rep Urol* 2015; 7: 65–79.
- Case records of the Massachusetts General Hospital. Weekly clinicopathological exercises. Case 29-1998. A 57-year-old man with fever and jaundice after intravesical instillation of bacille Calmette-Guérin for bladder cancer. *N Engl J Med* 1998; 339: 831–7.
- To U, Kim J, Chia D. Disseminated BCG: Complications of Intravesical Bladder Cancer Treatment. *Case Rep Med* 2014; 2014: 362845.
- Lamm DL, van der Meijden PM, Morales A et al. Incidence and treatment of complications of bacillus Calmette-Guérin intravesical therapy in superficial bladder cancer. *J Urol* 1992;147: 596–600.
- Gonzalez OY, Musher DM, Brar I et al. Spectrum of bacille Calmette-Guérin (BCG) infection after intravesical BCG immunotherapy. *Clin Infect Dis*. 2003; 36: 140–8.
- Perez-Jacoiste Asin MA, Fernandez-Ruiz M, Lopez-Medrano F et al. Bacillus Calmette-Guérin (BCG) infection following intravesical BCG administration as adjunctive therapy for bladder cancer: incidence, risk factors, and outcome in a single-institution series and review of the literature. *Medicine (Baltimore)* 2014; 93: 236–54.
- Graziano DA, Jacobs D, Lozano RG et al. A case of granulomatous hepatitis after intravesical bacillus Calmette-Guérin administration. *J Urol* 1991; 146: 1118–9.
- Leebeek FW, Ouwendijk RJ, Kolk AH et al. Granulomatous hepatitis caused by Bacillus Calmette-Guérin (BCG) infection after BCG bladder instillation. *Gut* 1996; 38: 616–8.